

Current Status of Skeletal Anchorage Dental Applications in Orthodontics, Part II

Authors

DIRK WIECHMANN, DDS, PhD*, **DAN GRAUER, DDS, PhD†**

Associate Editor

EDWARD J. SWIFT JR., DMD, MS

Skeletal anchorage (SA) has expanded treatment options not only for orthodontics but also for other dental disciplines. In the same way that dental movement can be produced in three planes of space, SA can be used in three dimensions to enhance the precision of orthodontic treatment and to allow for movements that are very difficult, if not impossible, with orthodontic treatment alone. The potential applications of SA should be incorporated into the dental diagnosis and treatment planning stage. A novel—but yet still difficult—application of SA is mesialization of posterior teeth into edentulous spaces.

ANTEROPosterior PLANE: PROTRACTION OF TEETH

Mesial movement of posterior teeth into missing teeth spaces is probably the most advantageous use of SA. The orthodontic-only (without SA) mesialization of posterior teeth is difficult, if not impossible to achieve without secondary effects on the teeth positioned anteriorly to the space.¹ The use of SA allows for stabilization of anterior teeth while posterior teeth are being pulled mesially, as an indirect source of anchorage, or allow for direct traction of the posterior segments.^{2–4} It is important to note that even with SA, mesial movement of posterior segments is slow and difficult. The most challenging cases involve

mesialization of second molars into an old extraction site that may display bone resorption.

VERTICAL PLANE

Intrusion of Teeth

Intrusion of teeth against SA devices (SA) or against other teeth anchored to a SA has been reported extensively.^{5–11} It is a reasonable application of SA, given that intrusion in the absence of SA is a difficult direction of movement in orthodontics.¹² Intrusion would be indicated in three main scenarios:

First, intrusion of anterior teeth in case of overerupted incisors. Current literature supports an intrusion of 2–3 mm without the use of SA¹² and describes this as difficult to achieve without producing unwanted effects on posterior teeth. The use of SA facilitates this type of orthodontic movement.^{13,14} *Second, absolute intrusion of posterior teeth in case of patients with increased anterior facial height or extruded posterior segments.* This type of movement is almost impossible without the use of SA. In these cases, mostly mini-plates and some mini-implants, allow for intrusion of molars up to 4–5 mm in the maxilla^{15–17} and 1.8–2.8 mm in the mandible.¹⁸ It has been reported that intrusion of posterior teeth undergoes 20% relapse during the first year after treatment and remains stable for the next 2 years.¹⁹

*Department of Orthodontics, Hannover Medical School, Hannover, Germany and Private Practice, Bad Essen, Germany

†Assistant Professor, University of Southern California and Private Practice, Los Angeles, CA, USA

Third, intrusion of localized overerupted teeth in case of absence of antagonist or ankylosis of antagonist. In this case, SA minimizes extrusion of neighboring teeth while leveling the overerupted tooth.^{20–22} It is important to note that a determination of bone levels is necessary to define the indication for intrusion, given that if bone levels are leveled in the overerupted position, a coronoplasty rather than intrusion is indicated. Intrusion in a case with leveled alveolar bone would produce a vertical bony defect.²³

Extrusion of Teeth

Extrusion of teeth using SA has been mainly described as adjuvants for extrusion of impacted teeth especially upper canines.^{24–26} Extrusion is also achievable without the use of SA. The main advantage of using temporary anchorage devices in the treatment of dental impactions is minimizing the reactive effects on neighboring teeth and decreasing the amount of time in fixed appliances.



FIGURE 1. Initial extraoral photos. Note the slightly long lower facial third. Patient’s chief complaints were uneven smile and missing upper left first molar.

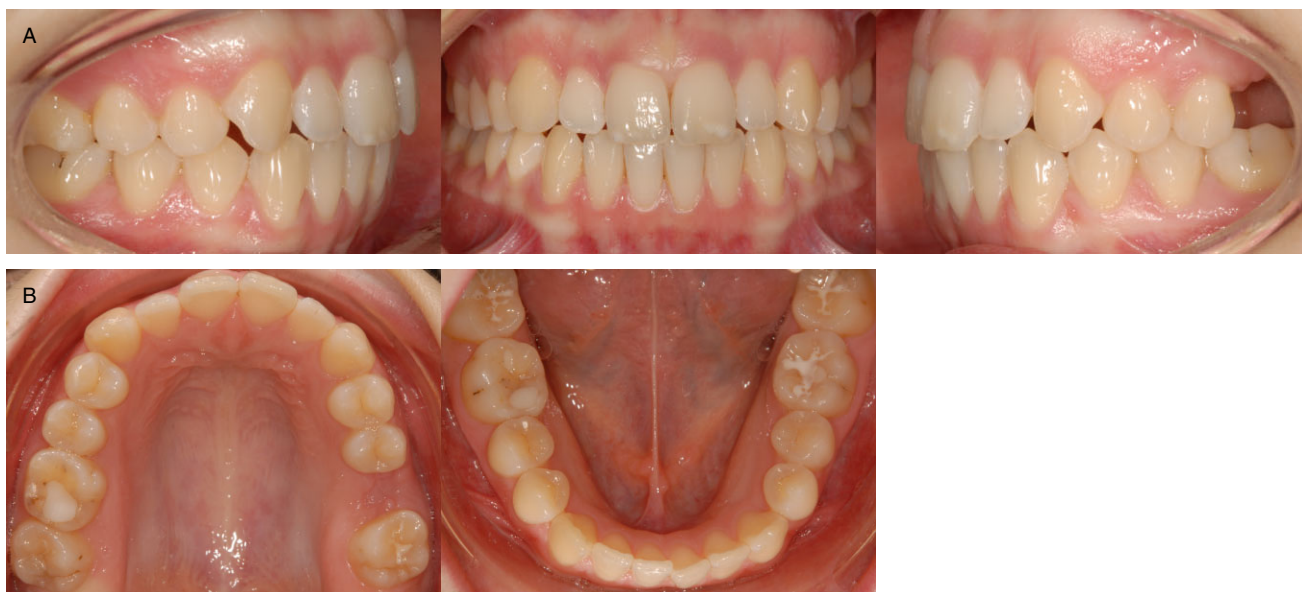

FIGURE 2. Initial intraoral photos. A, Rotation of upper canines and missing upper left first molar can be observed. Overbite is deficient. B, Upper left first molar was recently extracted due to a vertical fracture.

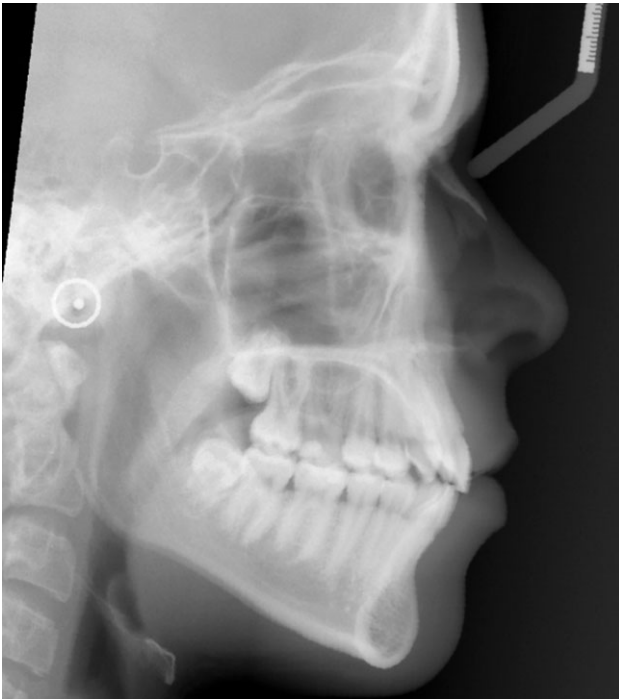


FIGURE 3. Cephalometric radiograph. Note the increased lower face height.

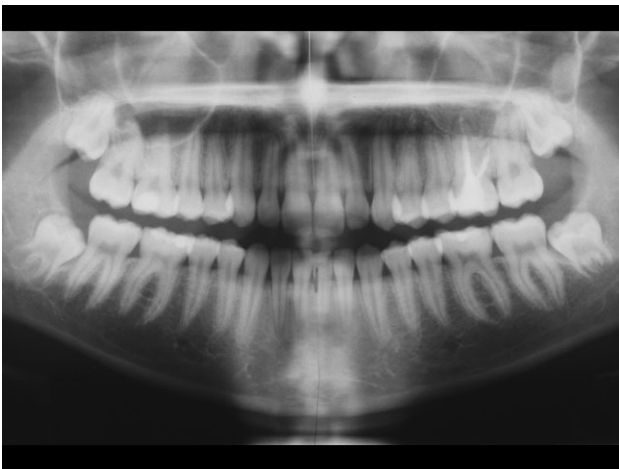


FIGURE 4. Panoramic radiograph was acquired before upper left first molar was diagnosed with a vertical fracture. Third molars are developing.

Transversal Plane

Correction of transverse problems by use of SA has been extensively reported in the literature.^{27–34} The use of skeletal anchored expanders minimizes the unwanted dental effects of conventional tooth-borne palatal

expanders. Nevertheless, the dental relapse of bone-borne expanders is also related to the pressures exerted by the cheeks and the stretch of the soft tissues, resulting in some unavoidable amount of relapse. Anteroposterior movement using SA involves changes in transverse relationships between upper and lower dental arches, and in many instances, this is to be avoided by the use of transpalatal arches to maintain intermolar distance. Unilateral problems are generally more difficult to treat than bilateral problems. The use of SA provides either stabilization of the side that does not need correction or selective force application to the side to be corrected.^{35–37}

Based on the current evidence, we have developed guidelines where dental movement assisted by SA is evaluated under three criteria: (1) whether the desired movement is possible, (2) whether it is reasonable to produce this direction of tooth movement, and (3) whether the result will be stable. Information regarding long-term stability is scarce, and further research is needed in order to adopt an evidence-based approach during treatment planning phase (see table II in Current Status of Skeletal Anchorage Dental Applications in Orthodontics Part I).

CLINICAL EXAMPLE II: PROTRACTION OF MOLARS

Diagnosis and Treatment Planning

Patient AH presented to the orthodontic clinic with chief complaints of uneven upper incisors, mild crowding of lower incisors, and recently extracted upper left first molar. The patient wanted to replace the missing molar with her second molar instead of an implant and prosthodontic restoration, and concomitantly correct the position of her incisors (Figure 1).

Based on clinical examination and initial records, her prioritized orthodontic problem list included:

- 1 Pathology concerns: the upper left first molar was extracted due to vertical fracture. The upper right

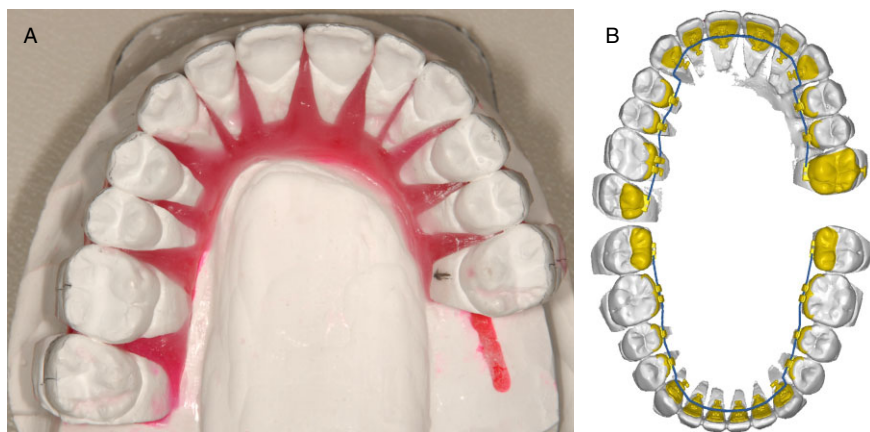


FIGURE 5. A, Diagnostic wax-up depicting the treatment objectives for upper arch. B, Appliances are virtually designed and fabricated on these scanned waxed-up models. Upper left second molar was brought into contact with upper left first molar, establishing a dental Class I occlusion with its antagonist.

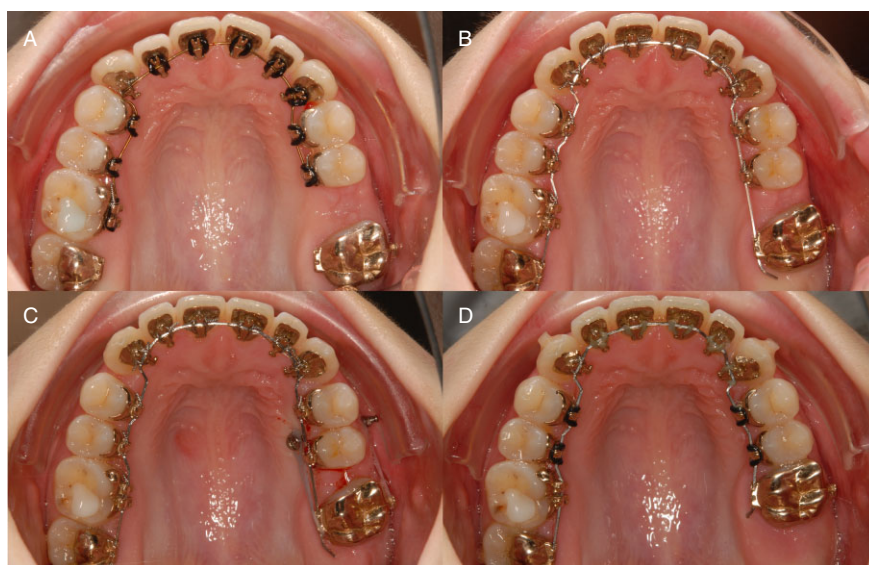

FIGURE 6. A, Customized brackets are bonded to the upper arch. Upper right second molar displays a half-occlusal pad while upper left second molar displays a full occlusal pad. B, A stainless steel wire is inserted in order to provide rigidity, while upper second is being pulled mesially. C, A combination of two mini-implants is used to apply a mesially directed force on upper left second molar. Double-cable mechanics—one elastic chain on the lingual side and one elastic chain on the labial side—are used to pull the upper left second molar into a mesial position. D, Space is close and tooth position is stabilized in a full-size wire.

- first molar had a large composite restoration in close proximity to the pulp chamber
- 2 Alignment/Symmetry: patient displayed 3-mm crowding in the upper dental arch, 3-mm crowding in the lower dental arch, and a 9-mm edentulous space upper left molar area (Figure 2)
- 3 Vertical: excess lower facial height and deficient overbite were noted (1 mm of overbite central

- incisors and 0.5 mm overbite lateral incisors, Figures 3 and 4)
- 4 Anteroposterior: patient had a skeletal Class I and dental Class I within normal limits
- 5 Transverse: upper and lower midlines were not coincident, with the lower midline positioned 1 mm to the right of upper midline
- 6 Soft tissue/Esthetics: incisor exposures at rest and at smile were within normal limits

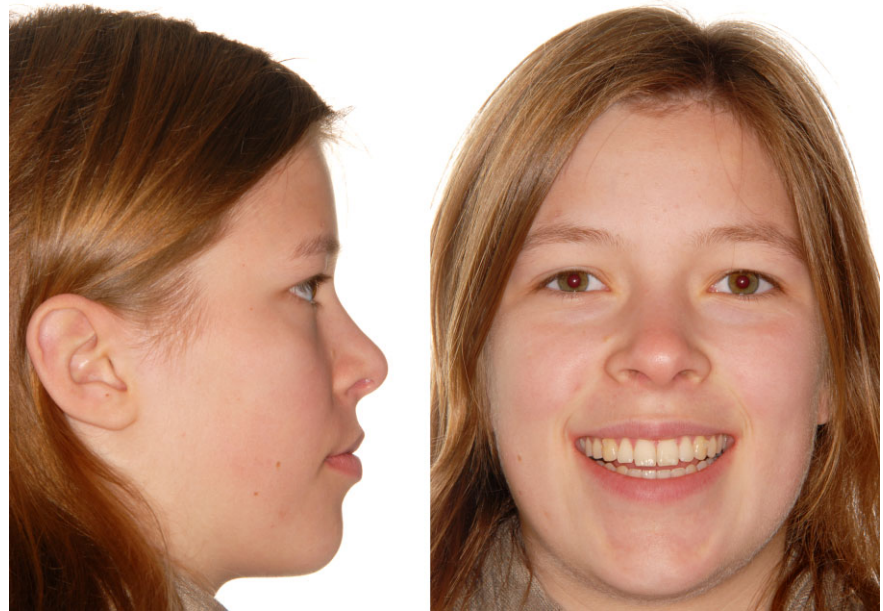

FIGURE 7. Extraoral photos on the day of appliance removal. Patient was very happy with the appearance of her smile.

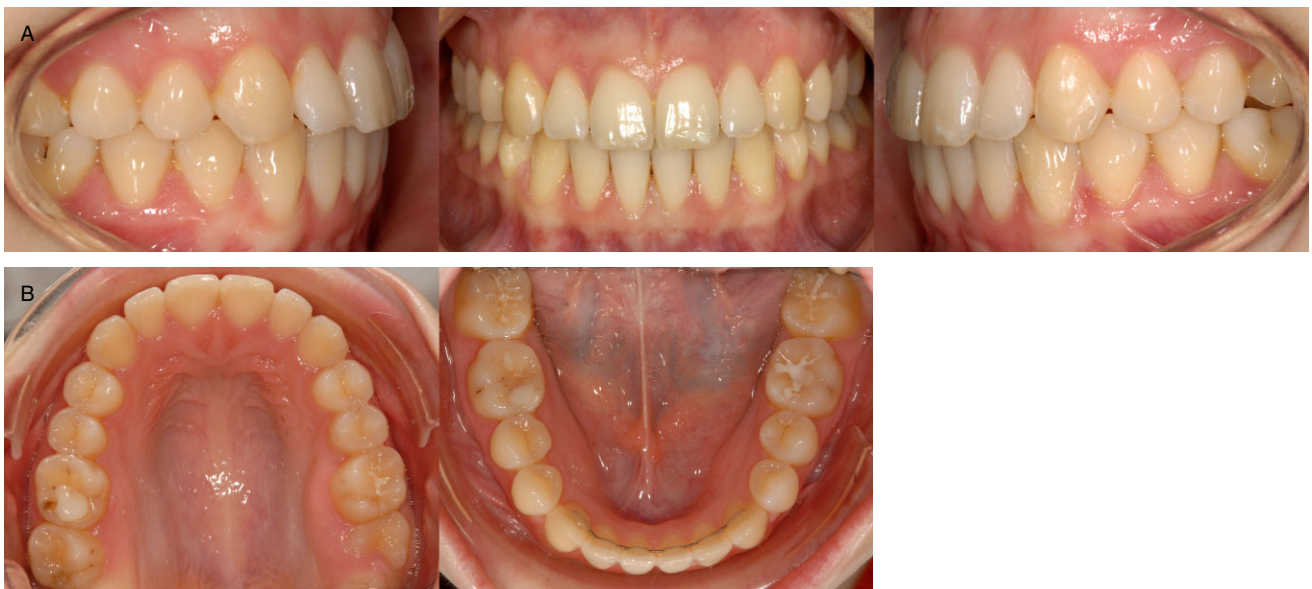

FIGURE 8. Final intraoral photos on the day of appliance removal. A, Class I dental occlusion was maintained bilaterally, and the upper left second molar was mesialized to the location of upper left first molar. A small amount of settling was expected due to the removal of an occlusal pad. Overbite was increased to 1.5 mm. B, All spaces were closed. Upper left third molar is partially erupted in the position of upper left second molar. A permanent bonded retainer was used to retain the position of lower incisors.

Treatment Objectives

- 1 Space closure by mesial movement of upper left second molar into the position of upper left first molar
- 2 Alignment of upper and lower incisors
- 3 Maintenance of anteroposterior dental occlusion
- 4 Slight extrusion of upper and lower incisors to establish an overbite of 2 mm
- 5 Permanent retention by splinting lower anterior teeth

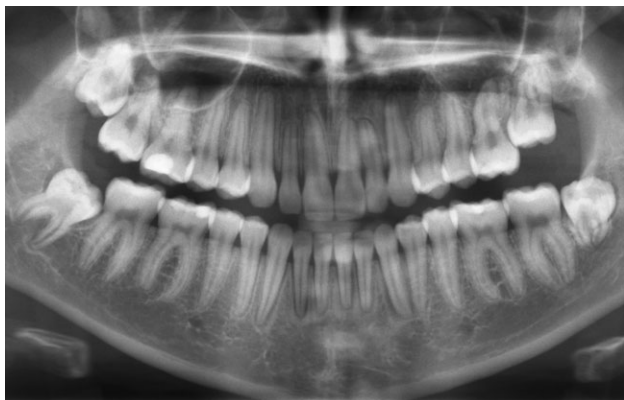


FIGURE 9. Panoramic radiograph on the day of appliance removal. Note the angulation of upper left second and third molars.

Treatment Plan and Mechanics

The treatment plan consisted of upper and lower fully customized lingual braces (Incognito, 3M Unitek, Bad Essen, Germany) to produce mesial movement of upper left second molar. Two microimplants—one on the labial side and one on the lingual side—were used to apply mesial force on upper left second molar, and that prevents moving all teeth anterior to the edentulous space distally while the upper left second molar was pulled mesially.

When fully customized lingual appliances are used, a diagnostic and therapeutic wax-up (appliances are built on this wax-up) is fabricated (Figure 5A and B). Wires are bent robotically to the desired orthodontic

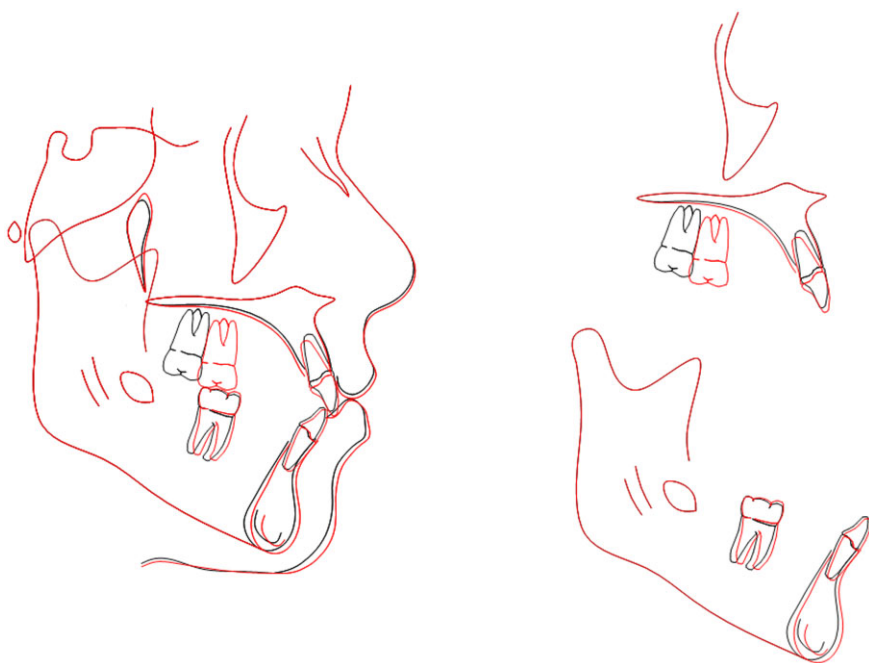


FIGURE 10. Superimposition of pretreatment and post-treatment cephalometric tracings. The change in molar position (upper second molar was traced), and the effects of treatment and growth can be observed.

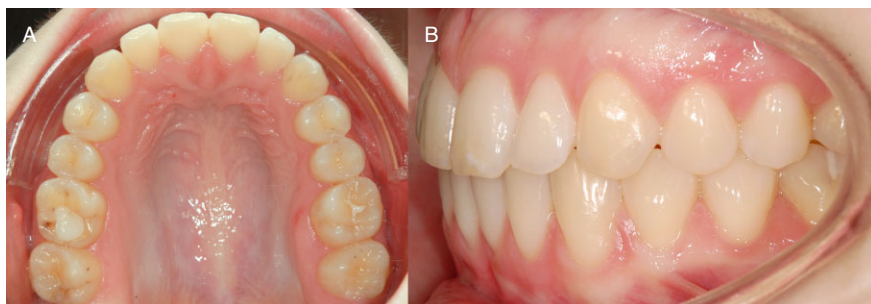

FIGURE 11. Seven months later. A, Upper left third molar erupted in the position of upper left second molar. B, Occlusion was stable, and upper left second molar settled into dental Class I occlusion.

outcome. Archwire progression involves an increase in rigidity of the wire as treatment evolves. Final detailing of the occlusion is achieved with full-size titanium molybdenum wires (Figure 6).

Treatment Outcomes

After 24 months of treatment, the upper left second molar substituted for the upper left first molar and was in Class I occlusion with its antagonist. Upper and lower teeth have been aligned, and overbite was increased to allow for better function (Figures 7–10). The patient was happy with her smile and appearance, and with the more conservative approach to the restoration of the missing upper left molar. The retention phase included a permanent bonded retainer to canines and lower incisors and a removable upper retainer. In a retention visit, 7 months after the removal of fixed appliances, the upper left third molar has erupted into the upper left second molar position (Figure 11).

CONCLUSIONS

SA has expanded the limits of orthodontic treatment. Teeth can be moved greater distances, more accurately, and without unwanted secondary effects. Use of SA also influences the diagnostic process when faced with missing teeth. A new treatment modality—even though not always indicated due to the difficulties it involves—is available to move teeth more precisely to replace missing teeth. When diagnosing a case, all solutions should be presented to the patient, and all members of the interdisciplinary team should be aware of each other approaches and limitations of treatment. Protracting teeth remains a very complex and often long orthodontic possibility, but with the help of SA is a predictable solution. SA can be used as an adjuvant to treatment in three dimensions of space.

ACKNOWLEDGMENT

The authors would like to thank Drs. J. F. Camilla Tulloch and William R. Proffit.

REFERENCES

- Jacobs C, Jacobs-Muller C, Luley C, et al. Orthodontic space closure after first molar extraction without skeletal anchorage. *J Orofac Orthop* 2011;72:51–60.
- Gedrange T, Boening K, Harzer W. Orthodontic implants as anchorage appliances for unilateral mesialization: a case report. *Quintessence Int* 2006;37:485–91.
- Faber J, Velasque F. Titanium miniplate as anchorage to close a premolar space by means of mesial movement of the maxillary molars. *Am J Orthod Dentofacial Orthop* 2009;136:587–95.
- Kyung SH, Choi JH, Park YC. Miniscrew anchorage used to protract lower second molars into first molar extraction sites. *J Clin Orthod* 2003;37:575–9.
- Lee SJ, Jang SY, Chun YS, Lim WH. Three-dimensional analysis of tooth movement after intrusion of a supraerupted molar using a mini-implant with partial-fixed orthodontic appliances. *Angle Orthod* 2013;83:274–279.
- Liou EJ, Chang PM. Apical root resorption in orthodontic patients with en-masse maxillary anterior retraction and intrusion with miniscrews. *Am J Orthod Dentofacial Orthop* 2010;137:207–12.
- Bonetti GA, Verganti S, Zanarini M, Graziani E. Orthodontic intrusion of posterior teeth using dental implant anchorage. *J Clin Orthod* 2008;42:222–5.
- Kravitz ND, Kusnoto B, Tsay PT, Hohlt WF. Intrusion of overerupted upper first molar using two orthodontic miniscrews. A case report. *Angle Orthod* 2007;77:915–22.
- Yao CC, Wu CB, Wu HY, et al. Intrusion of the overerupted upper left first and second molars by mini-implants with partial-fixed orthodontic appliances: a case report. *Angle Orthod* 2004;74:550–7.
- Ohmae M, Saito S, Morohashi T, et al. A clinical and histological evaluation of titanium mini-implants as anchors for orthodontic intrusion in the beagle dog. *Am J Orthod Dentofacial Orthop* 2001;119:489–97.
- Flieger S, Ziebur T, Kleinheinz J, Wiechmann D. A simplified approach to true molar intrusion. *Head Face Med* 2012;8:30.
- Ng J, Major PW, Flores-Mir C. True molar intrusion attained during orthodontic treatment: a systematic

- review. *Am J Orthod Dentofacial Orthop* 2006;130:709–14.
13. Senisik NE, Turkkahraman H. Treatment effects of intrusion arches and mini-implant systems in deepbite patients. *Am J Orthod Dentofacial Orthop* 2012;141:723–33.
 14. Aydogdu E, Ozsoy OP. Effects of mandibular incisor intrusion obtained using a conventional utility arch vs bone anchorage. *Angle Orthod* 2011;81:767–75.
 15. Park HS, Jang BK, Kyung HM. Maxillary molar intrusion with micro-implant anchorage (MIA). *Aust Orthod J* 2005;21:129–35.
 16. Kravitz ND, Kusnoto B, Tsay TP, Hohlt WF. The use of temporary anchorage devices for molar intrusion. *J Am Dent Assoc* 2007;138:56–64.
 17. Park YC, Lee HA, Choi NC, Kim DH. Open bite correction by intrusion of posterior teeth with miniscrews. *Angle Orthod* 2008;78:699–710.
 18. Sugawara J, Baik UB, Umemori M, et al. Treatment and posttreatment dentoalveolar changes following intrusion of mandibular molars with application of a skeletal anchorage system (SAS) for open bite correction. *Int J Adult Orthodon Orthognath Surg* 2002;17:243–53.
 19. Baek MS, Choi YJ, Yu HS, et al. Long-term stability of anterior open-bite treatment by intrusion of maxillary posterior teeth. *Am J Orthod Dentofacial Orthop* 2010;138(396):e391–9.
 20. Heravi F, Bayani S, Madani AS, et al. Intrusion of supra-erupted molars using miniscrews: clinical success and root resorption. *Am J Orthod Dentofacial Orthop* 2011;139(4 Suppl):S170–5.
 21. Lin JC, Liou EJ, Yeh CL. Intrusion of overerupted maxillary molars with miniscrew anchorage. *J Clin Orthod* 2006;40:378–83.
 22. Kato S, Kato M. Intrusion of molars with implants as anchorage: a report of two cases. *Clin Implant Dent Relat Res* 2006;8:100–6.
 23. Kokich VG, Spear FM. Guidelines for managing the orthodontic-restorative patient. *Semin Orthod* 1997;3(1):3–20.
 24. Kocsis A, Seres L. Orthodontic screws to extrude impacted maxillary canines. *J Orofac Orthop* 2012;73:19–27.
 25. Park HS, Kwon OW, Sung JH. Micro-implant anchorage for forced eruption of impacted canines. *J Clin Orthod* 2004;38:297–302.
 26. Nienkemper M, Wilmes B, Lubberink G, et al. Extrusion of impacted teeth using mini-implant mechanics. *J Clin Orthod* 2012;46:150–5.
 27. Jeon HJ, Park SH, Chun YS. Correction of posterior crossbite with a nickel titanium appliance and indirect skeletal anchorage. *J Clin Orthod* 2009;43:106–10.
 28. Lee KJ, Park YC, Park JY, Hwang WS. Miniscrew-assisted nonsurgical palatal expansion before orthognathic surgery for a patient with severe mandibular prognathism. *Am J Orthod Dentofacial Orthop* 2010;137:830–9.
 29. Wilmes B, Nienkemper M, Drescher D. Application and effectiveness of a mini-implant- and tooth-borne rapid palatal expansion device: the hybrid hyrax. *World J Orthod* 2010;11:323–30.
 30. Garib DG, Navarro Rde L, Francischone CE, Oltramari PV. Rapid maxillary expansion using palatal implants. *J Clin Orthod* 2008;42:665–71.
 31. Aziz SR, Tanchyk A. Surgically assisted palatal expansion with a bone-borne self-retaining palatal expander. *J Oral Maxillofac Surg* 2008;66:1788–93.
 32. Verstraaten J, Kuijpers-Jagtman AM, Mommaerts MY, et al. A systematic review of the effects of bone-borne surgical assisted rapid maxillary expansion. *J Craniomaxillofac Surg* 2010;38:166–74.
 33. Hansen L, Tausche E, Hietschold V, et al. Skeletally-anchored rapid maxillary expansion using the Dresden distractor. *J Orofac Orthop* 2007;68:148–58.
 34. Ramieri GA, Spada MC, Austa M, et al. Transverse maxillary distraction with a bone-anchored appliance: dento-periodontal effects and clinical and radiological results. *Int J Oral Maxillofac Surg* 2005;34:357–63.
 35. Chung KR, Choo H, Lee JH, Kim SH. Atypical orthodontic extraction pattern managed by differential en-masse retraction against a temporary skeletal anchorage device in the treatment of bimaxillary protrusion. *Am J Orthod Dentofacial Orthop* 2011;140:423–32.
 36. Paik CH, Ahn SJ, Nahm DS. Correction of Class II deep overbite and dental and skeletal asymmetry with 2 types

of palatal miniscrews. *Am J Orthod Dentofacial Orthop* 2007;131(4 Suppl):S106–16.

37. Yanagita T, Kuroda S, Takano-Yamamoto T, Yamashiro T. Class III malocclusion with complex problems of lateral open bite and severe crowding successfully treated with miniscrew anchorage and lingual orthodontic brackets. *Am J Orthod Dentofacial Orthop* 2011;139:679–89.

Contemporary Issues

Dan Grauer

University of Southern California and Private Practice
Los Angeles, CA 90067

USA

Telephone: 310-277-0755

E-mail: drgrauer@yahoo.com