

Memotain: A CAD/CAM nickel-titanium lingual retainer

Neal D. Kravitz,^a Dan Grauer,^{b,c} Pascal Schumacher,^d and Yong-min Jo^e

South Riding, VA, Santa Monica, Calif, Cologne, and Mettmann, Germany

Approximately 1/2 of maxillary and 1/5 of mandibular multi-stranded lingual retainers fail during retention in some form, either bond failure or wire breakage. Memotain is a new CAD/CAM fabricated lingual retainer wire made of custom-cut nickel-titanium, as an alternative to multi-stranded lingual retainers. It offers numerous perceived advantages to the traditional multi-stranded stainless steel wire, including precision fit, avoidance of interferences, corrosion resistance and even the potential for minor tooth movement as an active lingual retainer. (*Am J Orthod Dentofacial Orthop* 2017;151:812-5)

Lingual retainer wire technology has changed little over the last 40 years. The 2 most widely used retainers remain the thick (0.025 to 0.032 in) round stainless steel wire bonded only to the canines and the thin (0.0195 or 0.0215 in) multistranded wire bonded to the incisors and canines.¹ Multistranded wires have become more common for their improved esthetics and control of the mandibular incisors, although these retainers have significant drawbacks.

The primary problem of multistranded lingual wires is their high failure rate. Clinical studies indicate that 23% to 58% of maxillary retainers and 5% to 37% of mandibular retainers fail during retention in some form, either bond failure or wire breakage.²⁻¹² Other disadvantages include difficulty flossing, plaque accumulation, stretching of the wire causing malalignment or spacing, unraveling, introduction of unwanted torque,¹³ irritation to the tongue, and occlusal interference (for the maxillary retainer).

As a result of the need for frequent repair, many orthodontists are reluctant to provide bonded lingual retainers to their patients. Those who do frequently must

remove the wire for 1 of the above reasons at some point during retention. Today, lingual retainers, commonly referred to by patients as “permanent” retainers, are often just a temporary solution.

The purpose of the article is to introduce Memotain—a new CAD/CAM fabricated lingual retainer wire made of custom-cut nickel-titanium—as an alternative to multistranded lingual retainers. Memotain’s material properties, manufacturing process, bonding protocol, and potential advantages will be reviewed.

Memotain is a CAD/CAM fabricated lingual retainer made of 0.014 × 0.014-in rectangular nickel-titanium.¹⁴ The wire is highly flexible and custom cut to precisely adapt to the patient’s lingual tooth anatomy (*Fig 1*). It was invented in 2012 by an orthodontist, Pascal Schumacher. The name Memotain is a portmanteau from the combination of “memory” and “retainer” because of the uniqueness of using nickel-titanium for the lingual wire.

Although Memotain uses CAD/CAM, the wire material and manufacturing process differ from the SureSmile wire (OraMetrix, Richardson, Tex). SureSmile uses a copper-nickel-titanium wire bent by a robot hand; a split second of intense heat is applied during the bend to create plastic deformation.¹⁵ Memotain is not bent at all. Rather, the wire is cut from a nickel-titanium sheet—called a “blank”—similar to a scissors cutting a piece of paper. The result is a custom-cut wire with smooth curvatures. This type of fabrication is ideal, since bending sites increase the risk of wire fracture.

After the wire is cut from the nickel-titanium sheet, it is electropolished. Electropolishing uses electrolysis to clean a metal alloy. In this process, the wire is submerged in an ion-charged bath. Running a current through the

^aPrivate practice, South Riding, Va.

^bUSC Advanced Orthodontics, Santa Monica, Calif.

^cPrivate practice, Santa Monica, Calif.

^dPrivate practice, Cologne, Germany.

^eCA-Digital, Mettmann, Germany.

Pascal Schumacher invented Memotain, and Yong-min Jo is the CEO of CA-Digital. Neal Kravitz and Dan Grauer have completed and submitted the ICMJE Form for Disclosure of Potential Conflicts of Interest, and none were reported. Address correspondence to: Neal D. Kravitz, 25055 Riding Plaza, Suite 110, South Riding, VA 20152; e-mail, nealkravitz@gmail.com.

Submitted, August 2016; revised and accepted, November 2016.

0889-5406/\$36.00

© 2017 by the American Association of Orthodontists. All rights reserved.

<http://dx.doi.org/10.1016/j.ajodo.2016.11.021>

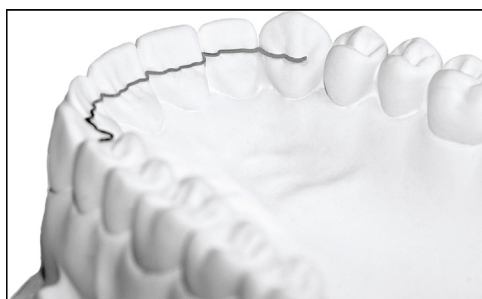

Fig 1. Memotain CAD/CAM nickel-titanium lingual wire with precision fit.

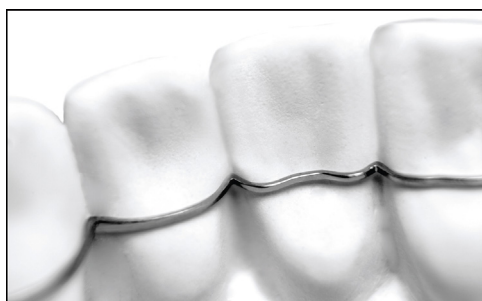

Fig 2. Closeup of Memotain after electropolishing. The wire is smooth, clean, and corrosion-resistant. The corners of the rectangular wire also are slightly rounded.

bath gradually removes material from the wire’s microscopic surface. As a result of electropolishing, the wire becomes brightened, cleaned, smoothed, polished, corrosion resistant, and less susceptible to microbial colonization. This process also causes the corners of the rectangular wire to be slightly rounded (Fig 2).

To place an order, the orthodontist can submit a polyvinylsiloxane impression or an intraoral scan in STL format. Memotain is digitally positioned to prevent occlusal interferences; therefore, if an impression is taken for a maxillary retainer, the orthodontist should also submit a mandibular impression with a bite registration. Typically, the orthodontist will submit the scan with the braces still on and bond the retainer before debanding; however, this is not possible with lingual braces. The custom lingual wire and a silicone putty transfer jig are mailed to the orthodontist in approximately 2 weeks (Fig 3).

The digitally planned position can be transferred clinically with less than 0.5 mm of error.¹⁶ Bonding the lingual retainer follows a traditional protocol of prophylaxis, etchant, primer, and placement of luting agent.¹⁷ A broad but thin application of luting agent is

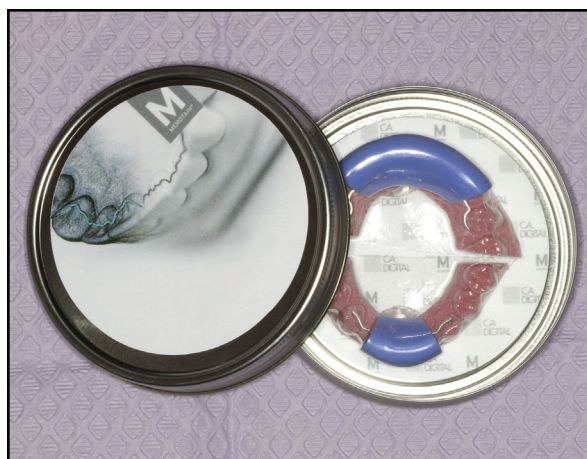

Fig 3. Memotain packaging.

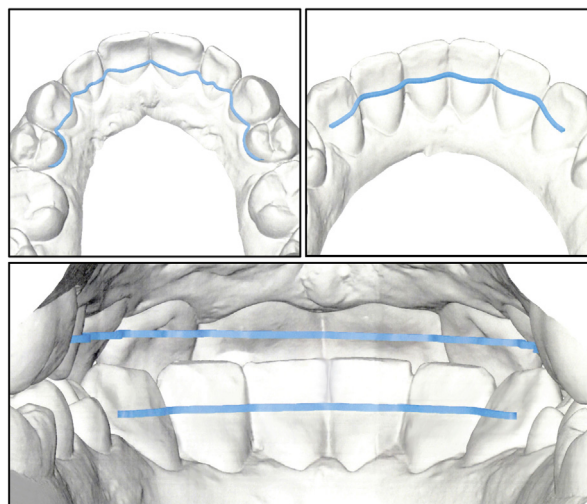


Fig 4. Memotain is digitally positioned to prevent interferences and designed to fit around atypical anatomy.

recommended to take advantage of the retainer’s custom fit. We advocate a nano-hybrid flowable resin, such as Tetric EvoFlow (Ivoclar Vivadent, Amherst, NY).

Memotain is manufactured by CA-Digital in Mettmann, Germany, and will soon be distributed by AOA Laboratory (Sturtevant, Wis) in the United States. Currently, the price for a single-arch Memotain retainer from canine to canine is €145, or approximately \$162 including shipping and handling to the United States; however, domestic distribution will cost significantly less. Memotain comes with a 24-month warranty.

Memotain offers numerous perceived advantages to traditional multistranded lingual wires, including no need for wire measuring or bending, individually

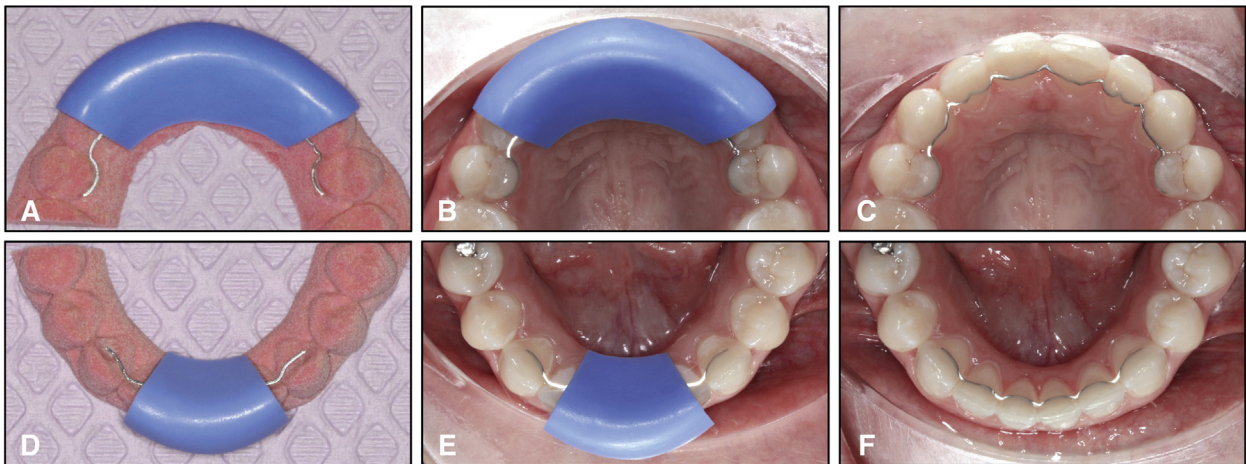


Fig 5. **A**, Maxillary Memotain on 3-dimensional printed model with putty transfer jig; **B**, end points bonded with composite; **C**, jig removed and remaining teeth bonded; **D**, mandibular Memotain on 3-dimensional printed model with putty transfer jig; **E**, end points bonded with composite; **F**, jig removed and remaining teeth bonded.

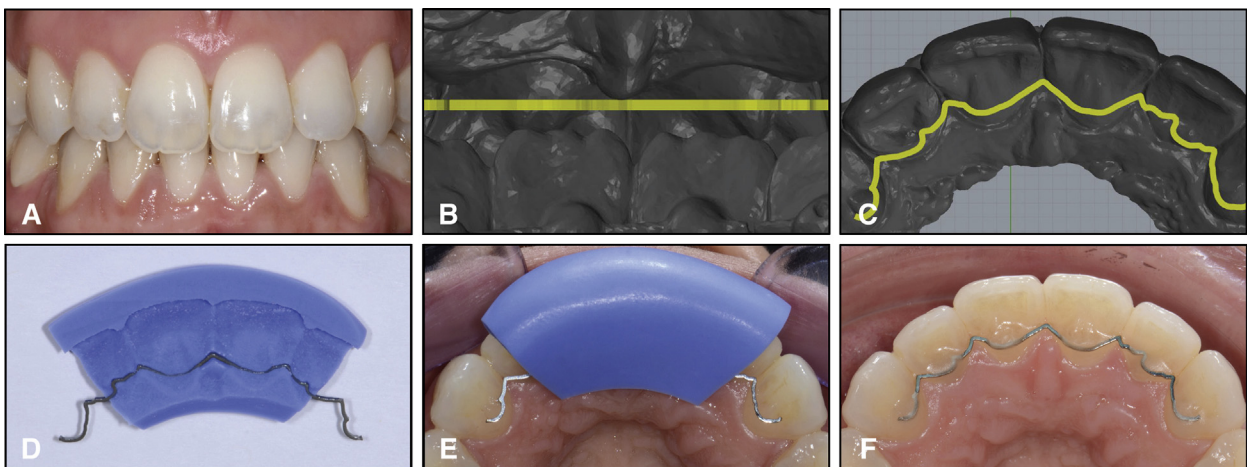


Fig 6. **A**, Functional occlusion with 4 mm of overbite makes maxillary retainer placement and positioning difficult; **B** and **C**, Memotain retainer designed to prevent interferences with occlusion (note the conventional multistranded retainer over the mandibular dentition); **D** and **E**, putty transfer jig; **F**, Memotain precision bonded.

optimized placement, greater accuracy of fit, tighter interproximal adaptation, less tongue irritation, better durability, and resistance to microbial colonization. However, clinical trials are necessary to determine whether these advantages are substantiated with scientific data.

This retainer may be most advantageous in the maxillary arch, where multistranded wires frequently fail. Maxillary anterior teeth commonly have large marginal ridges or atypical shapes (ie, peg-shaped lateral incisors, talon cusps, invaginations) that make close adaptation

with hand-bent wires challenging. Memotain's tight interproximal wrap is beneficial in common break-point areas, such as the embrasure between the lateral incisor and the canine, or the step between the canine and the premolar. Furthermore, it is digitally positioned to prevent contact with the mandibular teeth (Fig 4).

Of particular interest is the potential for Memotain to provide minor tooth alignment. The idea of applying a nickel-titanium wire as an "active" lingual retainer was first reported by Liou et al¹⁸ in 2001.

Memotain's precision fit and memory enable its use passively for tooth maintenance, as well as actively to retreat mild mandibular anterior crowding without the need for brackets. For example, if an incisor detaches and moves slightly out of position, the orthodontist can simply rebond the flexible wire actively to help the tooth realign. The simplest technique is using floss loops threaded interproximally to secure the wire to the displaced tooth.

Patient 1

A 26-year-old woman received maxillary and mandibular Memotain retainers after 23 months of orthodontic treatment. Her treatment plan entailed maxillary first premolar extractions to camouflage her mandibular retrognathia and Class II Division 1 malocclusion. After debanding, she was retained with circumferential Hawley-type retainers for 3 months to enable settling, before transitioning to fixed retention at her request.

The Memotain prescription and digital scan were uploaded on line at <https://order.ca-digit.com>. The maxillary retainer was designed to extend to the second premolars to hold consolidation of the extraction spaces, since this can be challenging in adult patients. The order arrived at the office in 6 days. The retainers were bonded using the putty jig and Tetric Evoflow. The end teeth were cured first with the jig in place, and then the jig was removed to cure the remaining teeth. Both retainers were bonded in less than 10 minutes with no need for equilibration (Fig 5).

Patient 2

A 29-year-old woman was not comfortable with a removable retainer for her maxillary teeth and requested a bonded retainer. Because of her overbite, there was not enough occlusal clearance to place a conventional multistranded lingual retainer (Fig 6). A Memotain retainer was designed to fit her maxillary incisors without interfering with her occlusion. The retainer was transferred to the patient's mouth according to the indicated protocol.

CONCLUSIONS

Memotain is a custom-cut CAD/CAM nickel-titanium wire that is a marked advancement in lingual retainer technology. It offers potential advantages to the traditional multistranded stainless steel wire, including precision fit, avoidance of interferences, corrosion resistance,

and even minor tooth movement as an active lingual retainer.

REFERENCES

1. Heymann GC, Grauer D, Swift EJ Jr. Contemporary approaches to orthodontic retention. *J Esthet Restor Dent* 2012;24:83-7.
2. Schneider E, Ruf S. Upper bonded retainers. *Angle Orthod* 2011;8:1050-6.
3. Becker A, Goultschin J. The multi-stranded retainer and splint. *Am J Orthod Dentofacial Orthop* 1984;85:470-4.
4. Zachrisson BU. Long-term experience with direct-bonded retainers: update and clinical advice. *J Clin Orthod* 2007;41:728-37.
5. Dahl EH, Zachrisson BU. Long-term experience with direct-bonded lingual retainers. *J Clin Orthod* 1991;25:619-30.
6. Årtun J, Spadafora AT, Shapiro PA. A 3-year follow-up study of various types of orthodontic canine-to-canine retainers. *Eur J Orthod* 1997;19:501-9.
7. Renkema AM, Renkema A, Bronkhorst E, Katsaros C. Long-term effectiveness of canine-to-canine bonded flexible spiral wire lingual retainers. *Am J Orthod Dentofacial Orthop* 2011;139:614-21.
8. Lie Sam Foek DJ, Ozcan M, Verkerke GJ, Sandham A, Dijkstra PU. Survival of flexible, braided, bonded stainless steel lingual retainers: a historic cohort study. *Eur J Orthod* 2008;30:199-204.
9. Aldrees AM, Al-Mutairi TK, Hakami ZW, Al-Malki MM. Bonded orthodontic retainers: a comparison of initial bond strength of different wire-and-composite combinations. *J Orofac Orthop* 2010;71:290-9.
10. Taner T, Aksu M. A prospective clinical evaluation of mandibular lingual retainer survival. *Eur J Orthod* 2012;34:470-4.
11. Naraghi S, Andren A, Kjellberg H, Mohlin BO. Relapse tendency after orthodontic correction of upper front teeth retained with a bonded retainer. *Angle Orthod* 2006;76:570-6.
12. Lumsden KW, Saidler G, McColl JH. Breakage incidence with direct-bonded lingual retainers. *Br J Orthod* 1999;26:191-4.
13. Pazera P, Fudalej P, Katsaros C. Severe complication of a bonded mandibular lingual retainer. *Am J Orthod Dentofacial Orthop* 2012;142:406-9.
14. Schumacher P. CAD/CAM-fabricated lingual retainers made of nitinol. *Dent Tribune* 2015. Available at: http://www.dental-tribune.com/articles/specialties/orthodontics/24257_cad_cam-fabricated_lingual_retainers_made_of_nitinol.html Accessed May 1, 2016.
15. Sachdeva RC. SureSmile technology in a patient-centered orthodontic practice. *J Clin Orthod* 2001;35:245-53.
16. Wolf M, Schumacher P, Jäger F, Wego J, Fritz U, Korbacher-Steiner H, et al. Novel lingual retainer created using CAD/CAM technology: evaluation of its positioning accuracy. *J Orofac Orthop* 2015;76:164-74.
17. Kravitz ND, Shirk JM. Bonded lingual retainers. *Orthod Products* 2015. Available at: <http://www.orthodonticproducts.com/2015/11/bonded-lingual-retainers/>. Accessed May 1, 2016.
18. Liou EJ, Chen LI, Huang CS. Nickel-titanium mandibular bonded lingual 3-3 retainer: for permanent retention and solving relapse of mandibular anterior crowding. *Am J Orthod Dentofacial Orthop* 2001;119:443-9.